

# Effect of Intraarticular Injection of Autologous Adipose-Derived Mesenchymal Stem and Regenerative Cells on Clinical Signs of Chronic Osteoarthritis of the Elbow Joint in Dogs\*

Linda L. Black, DVM, PhD<sup>a</sup>  
James Gaynor, DVM, MS, DACVA, DAAPM<sup>b</sup>  
Cheryl Adams, DVM, CVA, CCRT<sup>c</sup>  
Sarit Dhupa, BVSc, DACVS<sup>d</sup>  
Andrew E. Sams, DVM, MS, DACVS<sup>e</sup>

Robert Taylor, DVM, DACVS<sup>f</sup>  
Susan Harman, AHT, BS<sup>a</sup>  
Daniel A. Gingerich, DVM, MS<sup>g</sup>  
Robert Harman, DVM, MPVM<sup>a,†</sup>

<sup>a</sup>*Vet-Stem, Inc.*  
12860 Danielson Court, Suite B  
Poway, CA 92064

<sup>b</sup>*Animal Anesthesia & Pain Management Center*  
5520 North Nevada Avenue, Suite 150  
Colorado Springs, CO 80918

<sup>c</sup>*Arboretum View Animal Hospital*  
2551 Warrenville Road  
Downers Grove, IL 60515

<sup>d</sup>*California Veterinary Specialists*  
2310 Faraday Avenue  
Carlsbad, CA 92008

<sup>e</sup>*The Andrew Sams Clinic*  
Orthopedic Surgery and Arthroscopy  
489 Miller Avenue  
Mill Valley, CA 94941

<sup>f</sup>7670 S. Dunkirk Street  
Centennial, CO 80016

<sup>g</sup>*Turtle Creek Biomedical Consulting*  
2219 Wilmington Road  
Lebanon, OH 45036

## CLINICAL RELEVANCE

Autologous adipose-derived mesenchymal stem cell (AD-MSC) therapy involves harvesting fat from the patient, isolating the stem and regenerative cells, and administering the cells back to the patient. Autologous AD-MSC therapy in veterinary regenerative medicine has been commercially available since 2003. Previously reported results from a blinded, controlled trial in dogs with chronic osteoarthritis of the coxofemoral (hip) joint demonstrated efficacy of a single intraarticular injection of autologous AD-MSC therapy. The primary objective of the current study was to evaluate the effectiveness of this therapy in dogs with chronic osteoarthritis of the humeroradial (elbow) joints and to determine the duration of effect. Fourteen dogs were recruited. Veterinarians assessed each dog for lameness, pain on manipulation, range of motion, and functional disability using a numeric rating scale at baseline and specified intervals up to 180 days after treatment. Statistically significant improvement in outcome measures was demonstrated.

\*This study was sponsored by Vet-Stem, Inc. Poway, California.

†Correspondence should be sent to Dr. Harman (Bharman@vet-stem.com).

## ■ INTRODUCTION

The field of adipose-derived mesenchymal stem cell (AD-MSC) therapy in regenerative medicine is a rapidly growing area of research, and stem cell therapy is being used to treat osteoarthritis (OA).<sup>1-9</sup> Isolation of cells from adipose tissue entails mincing and washing followed by enzyme digestion, washing, and centrifugation.<sup>8,10</sup> The pellet formed from centrifugation, often termed the stromal vascular fraction, is a heterogeneous mixture of cells including fibroblasts, pericytes, endothelial cells, blood cells, and AD-MSCs and is the treatment modality for these studies.<sup>8,11-13</sup> Since 2003, veterinarians have used autologous AD-MSCs to treat tendon and ligament injuries and joint disease in horses on a commercial basis.<sup>14-16</sup> As a result of the “minimally manipulated” nature of the cells, this particular autologous stem cell therapy does not require FDA approval.

Studies and anecdotal clinical experience demonstrate that autologous AD-MSC therapy is of clinical benefit in horses and dogs with orthopedic conditions.<sup>14-17</sup> A number of recent publications provide evidence of therapeutic success with AD-MSC therapy.<sup>9,18-20</sup> Nathan and colleagues demonstrated that cultured AD-MSCs in a fibrin carrier were better able to fill osteochondral defects created in rabbit femoral condyles than the fibrin carrier alone, and the biomechanical performance of the AD-MSC-treated group was clearly superior as well.<sup>20</sup> Using an equine tendonitis model in a blinded, placebo-controlled study, Nixon and associates demonstrated that AD-MSC-treated horses had statistically significant improvement in inflammatory cell infiltrate, collagen fiber uniformity, polarized collagen fiber crimping, overall tendon healing score, and collagen oligomeric matrix protein scores.<sup>16,17</sup> Finally, using a numeric rating scale in a double-blinded, controlled trial, Black et al dem-

onstrated that dogs with chronic OA of the hip joint were statistically significantly improved after intraarticular injection of AD-MSCs.<sup>9</sup> Used commercially in more than 2,500 horses and more than 500 dogs with no systemic adverse events and less than 1.0% (equine) and 0.5% (canine) local tissue reactions (as of January 2008),<sup>15</sup> autologous AD-MSC therapy is reasonably safe and therapeutically successful in veterinary medicine.

In the United States, OA is the most common cause of chronic pain in dogs, with more than 20%, or 10 to 12 million dogs, afflicted.<sup>21-23</sup> OA is characterized by synovitis and degeneration of the articular cartilage with loss of matrix and can result in complete loss of the cartilage surface.<sup>24</sup> Chondrocytes, the only cells of articular cartilage, maintain homeostatic synthesis and degradation of the extracellular matrix via the secretion of macromolecular components (collagen, glycosaminoglycans, and hyaluronic acid) and modulation of the extracellular matrix turnover. Chondrocyte secretion of lytic and tissue-damaging mediators (cytokines, free radicals, proteases, prostaglandins) are controlled by a balance of anabolic and reparative substances (growth factors, inhibitors of catabolic cytokines) and inhibitors of degradative enzymes.<sup>24</sup> In OA, there exists an overproduction of destructive and proinflammatory mediators relative to the inhibitors, resulting in a balance in favor of catabolism rather than anabolism, which in turn leads to the progressive destruction of articular cartilage.<sup>24</sup>

With so many dogs affected with OA and evidence suggesting that NSAIDs many times do not provide complete pain relief,<sup>25-29</sup> AD-MSC therapy may provide a therapeutic alternative. The purpose of this pilot study was to evaluate the clinical effect of a single intraarticular injection of AD-MSCs in dogs with OA of the elbow joint.

## ■ MATERIALS AND METHODS

### Study Population

Four companion animal regional referral veterinary practices in the United States participated in this study, which included 14 outpatient dogs with chronic OA of the elbow joint. Investigators included three diplomates of the American College of Veterinary Surgeons, one diplomate of the American Association of Pain Management, and one veterinarian certified in veterinary acupuncture practicing in a large referral hospital. Dogs had a history of a previously fragmented coronoid process with surgical removal and/or osteochondritis dissecans.

Before enrollment, investigators ensured that all dogs underwent routine clinical chemistry and hematology (complete blood cell count) evaluation (conducted at an outside laboratory) to ensure overall health. Study ani-

degenerative change (no osteophytes)

2 = Mild degenerative change (occasional osteophytes)

3 = Moderate degenerative change (osteophytes, subchondral sclerosis)

4 = Severe degenerative change (osteophytes, subchondral sclerosis, bone remodeling)

Dogs were excluded from the study if they had concurrent disease, such as a fungal, bacterial, or viral infection; malignant neoplasia; or any severe systemic disease that would confound interpretation of treatment effects. All enrolled dogs were deemed healthy with no systemic disease.

Dogs that were on concomitant therapy, such as NSAIDs, were required to be on these medications for at least 60 days before enrollment in the study and to remain on the

---

*With so many dogs affected with OA and evidence suggesting that NSAIDs many times do not provide complete pain relief, AD-MSK therapy may provide a therapeutic alternative.*

---

mals demonstrated gait changes characteristic of OA, including persistent lameness at a walk and trot, pain on passive manipulation of the affected joint(s), limited range of motion with pain at less than full range of passive motion, and functional disabilities as measured by willingness to walk and run.

Each qualified case demonstrated pretreatment radiographic evidence of degenerative joint disease, as evaluated by the investigator, of grade 2 or higher on the following radiographic scoring scale:

0 = Normal joint

1 = Radiographic evidence of instability; no

drugs at the same level throughout the study. Hyaluronic acid and polysulfated glycosaminoglycan injections, nutraceuticals, corticosteroids, and such alternative treatments as chiropractic and acupuncture, if used, were discontinued in all dogs beginning 10 days before enrollment in the study and were not administered during the study period.

To be eligible, the dogs had to be cared for by attentive owners who agreed by informed consent to participate in this clinical study, to follow a set schedule of veterinary appointments, and to observe their dog for the entire study period.

## Treatments

The in-house laboratory at Vet-Stem prepared the test treatment material for each study dog. Laboratory technicians isolated autologous AD-MSCs from a minimum of 15 g of adipose collected from each dog by the investigator. Laboratory personnel provided the test material to the investigator in sterile 1-ml syringes. Each dog received 3 million to 5 million viable cells prepared from the dog's own adipose tissue in 0.6 ml phosphate buffered saline (PBS) per joint. The cells were injected into single, aseptically prepared sites on both elbow joints; dogs were sedated for the injection.

Owners were counseled to leash-walk their dogs twice daily or to continue on a previously prescribed rehabilitation program.

## Stem and Regenerative Cell Preparation

### *Adipose Tissue Collection*

Adipose tissue was collected from either the abdominal, inguinal, falciform ligament, or thoracic wall regions of the dogs. A small (5 cm) surgical incision was made aseptically after the patient was anesthetized. The adipose tissue was resected by scalpel or surgical scissors and placed into a labeled sterile tube containing 15 ml of PBS. The sample tube was placed in a validated, temperature-controlled 2°C to 8°C transport box specially fitted with a frozen cold pack and shipped overnight to the Vet-Stem laboratory for processing.

### *Tissue Processing for Stem and Regenerative Cell Isolation*

Adipose tissue was washed with PBS, minced, washed several more times with PBS to remove debris and excess blood, and centrifuged as previously reported.<sup>9</sup> An aliquot of the final cell suspension was assessed for viability (trypan blue exclusion method) and total nucleated cell yield. This constitutes the stromal vascular fraction preparation, which con-

sists of a heterogenous mixture of cells including AD-MSCs, hematopoietic stem cells, pre-endothelial cells, fibroblasts, pericytes, and endothelial cells.<sup>8,11-13</sup>

## Evaluations

Veterinary evaluation incorporated history, physical examination, and lameness examination including joint mobility, notation of pain on manipulation, and functional disability. Clinical outcome measures were based on veterinary orthopedic examination evaluation by a single investigator using the following numeric rating scale:

- **Lameness at walk and trot:** 1 (normal), 2 (intermittent), 3 (persistent), 4 (non-weight-bearing), 5 (ambulatory only with assistance), 6 (nonambulatory)
- **Pain on manipulation:** 1 (no pain), 2 (mild pain; attempts to withdraw limb), 3 (severe; immediately withdraws limb)
- **Range of motion:** 1 (normal), 2 (pain only at full range of motion), 3 (pain at less than full range of motion), 4 (pain on any joint manipulation)
- **Functional disability:** 1 (normal; no stiffness), 2 (slightly stiff gait noticeable only on running), 3 (stiff; dog has noticeable stiffness while walking and running), 4 (very stiff; dog does not want to walk or run without being coaxed), 5 (does not want to walk; will not run; must be helped up)

Baseline results for both owner and veterinary evaluations were recorded before adipose tissue harvest and between 2 and 14 days before the dogs received AD-MSC therapy by intraarticular injection. Follow-up visits to the veterinary clinic were required at 30, 60, 90, and 180 days after the dog's intraarticular injection. At each visit, owners were also asked to complete a numeric rating scale (1 [best] to 5 [worst]) as

**TABLE 1. Orthopedic Examination Scores (mean ± SEM) in 14 Dogs with Osteoarthritis of the Elbow Joint before and after Intraarticular Injection of Autologous Adipose Derived Mesenchymal Stem Cells\***

<i>Time</i>	<i>Lameness at Walk</i>	<i>Lameness at Trot</i>	<i>Pain on Manipulation</i>	<i>Joint Stiffness</i>	<i>Functional Disability</i>	<i>Composite Score</i>
Baseline	2.7 ± 0.14	2.9 ± 0.08	2.1 ± 0.08	2.7 ± 0.13	3.0 ± 0.23	13.3 ± 0.51
30 days	2.2 ± 0.20	2.3 ± 0.19	1.8 ± 0.11	2.3 ± 0.14	2.2 ± 0.20	10.6 ± 0.69
60 days	2.1 ± 0.22	2.3 ± 0.19	1.8 ± 0.13	2.1 ± 0.18	2.1 ± 0.20	10.3 ± 0.79
90 days	1.7 ± 0.22	2.0 ± 0.21	1.8 ± 0.09	2.0 ± 0.14	1.7 ± 0.18	9.2 ± 0.70
180 days	1.7 ± 0.24	1.8 ± 0.25	1.8 ± 0.10	2.3 ± 0.16	1.6 ± 0.23	9.2 ± 0.82
Significance†	<i>P</i> < .001	<i>P</i> = .002	<i>P</i> = .108 (NS)	<i>P</i> = .002	<i>P</i> < .001	<i>P</i> < .001

\*Individual scores for various parameters: lameness, 1 (normal) to 6 (nonambulatory); pain, 1 (no pain) to 3 (severe); range of motion (stiffness), 1 (normal) to 4 (pain on any joint manipulation); functional disability, 1 (normal; no stiffness) to 5 (does not want to walk); composite score maximum, 24.

†Repeated measures analysis of variance on ranks.

NS = not significant.

part of a standard questionnaire adapted from the Cincinnati Orthopedic Disability Index (CODI),<sup>30</sup> which included evaluation of the following 13 parameters: walk, run, jump, turning suddenly, getting up from lying down, lying down from standing, climbing stairs, descending stairs, squatting to urinate or defecate, stiffness in the morning, stiffness in the evening, difficulty walking on slippery floors, and willingness to play voluntarily.

**Statistical Evaluation**

The statistical significance of changes in veterinarian and owner clinical scores over time from baseline values was analyzed separately by repeated measures analysis of variance on ranks. All comparisons were made at the nominal .05 level of significance. To provide an estimate of the practical relevance of the apparent effects of treatment, the standardized treatment effect,<sup>31,32</sup> defined as the mean change from baseline divided by the standard deviation of the change, was calculated for each outcome variable at

each posttreatment evaluation. The significance of correlations between veterinarian and owner scores was determined by the Spearman rank order correlation method.

**RESULTS**

Fourteen dogs (six spayed females and eight neutered males) ranging in age from 10 months to 11 years were recruited based on the presence of OA of the elbow joint. The breeds included bullmastiff, golden retriever, golden retriever cross, Labrador retriever, Labrador retriever cross, Newfoundland, sheltie, and springer spaniel. Of the 14 dogs enrolled in the elbow study, 11 had bilateral elbow disease and were given AD-MSCs in both joints. The physical examination scores, which usually were identical between contralateral limbs, were combined and expressed as the average of each individual physical score for each dog.

Clinical outcomes after therapy improved markedly compared with baseline as determined by decreasing veterinarian physical ex-

amination scores over time (Table 1). These changes were statistically significant ( $P < .005$ ) with regard to all individual physical examination outcome variables except pain on manipulation and in composite scores assigned by the veterinary investigators.

The greatest improvements, 30% to 40%, were detected in functional disability and lameness, whereas pain on manipulation of the joints was not as prominent a feature of the involved joints and showed less change (Figure 1).

Owner-assessed outcomes also improved significantly ( $P < .001$ ) by an average of more than 30% (Table 2).

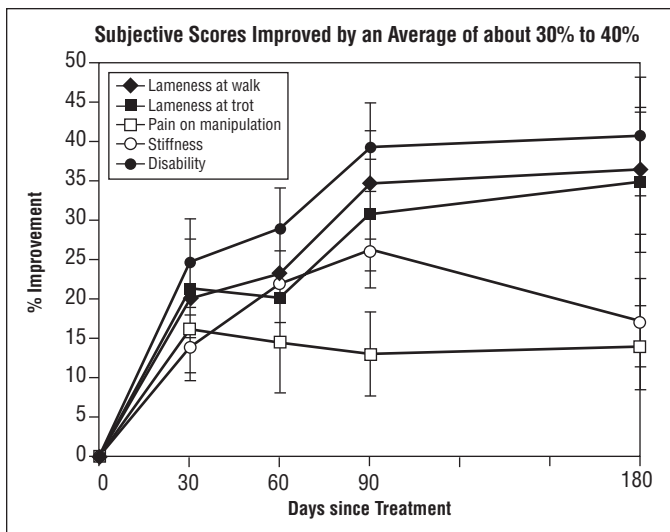
The standardized effect size for the composite improvement scores 180 days after stem cell therapy was 1.7 and 1.4 for the veterinarian and owner, respectively.

### Correlations between Veterinarian and Owner Scores

Inasmuch as all dogs were evaluated both by skilled veterinary investigators and independently by their owners at the same time points, it was possible to compare outcomes by both scoring systems. In both studies the investigator clinical scores correlated significantly ( $P < .001$ ) with owner scores, suggesting reliability and relevance of owners' observations. The calculated correlation coefficients between veterinarians and owners were 0.564 ( $n = 65$ ).

### DISCUSSION

Results of this study demonstrate that intra-articular AD-MSC therapy resulted in improved orthopedic examination scores for lameness and



**Figure 1.** Degree of improvement in orthopedic examination scores in dogs with osteoarthritis of the elbow after intraarticular injection of autologous adipose-derived mesenchymal stem cells (% change; mean  $\pm$  SEM;  $N = 14$ ).

range of motion (joint stiffness), as well as their overall combined scores, as assessed by skilled veterinarians, for OA of the elbow. The owner scores also revealed a significant improvement in lameness, stiffness, and pain over time. These data are significant and the veterinary and owner outcomes were highly correlative, indicating that the owners also perceived what the professional examinations demonstrated. These results are consistent with the original report by Black et al<sup>9</sup> demonstrating that dogs with chronic OA of the hip joints treated with a single intraarticular injection of AD-MSCs significantly improved from baseline over time and compared with saline-injected placebo controls.<sup>9</sup> The current study also expands on the original 90-day hip trial in that it indicates that the duration of effect is at least 180 days. These data provide additional evidence for the lasting effect of AD-MSC therapy in alleviating pain and lameness in dogs with OA.

Even though these were not placebo-controlled studies, the large calculated effect size

**TABLE 2. Owner-Assessed Disability Scores (mean ± SEM) in 14 Dogs with Osteoarthritis of the Elbow Joint before and after Intraarticular Injection of Autologous Adipose-Derived Mesenchymal Stem Cells\***

Time	Composite Score	% Improvement
Baseline	29.5 ± 2.46 <sup>†</sup>	—
30 days	20.0 ± 1.30 <sup>†</sup>	28.5% ± 4.7% <sup>†</sup>
60 days	18.9 ± 1.52 <sup>†</sup>	34.0% ± 3.8% <sup>†</sup>
90 days	16.6 ± 1.10 <sup>†</sup>	37.5% ± 4.0% <sup>†</sup>
180 days	17.0 ± 1.13 <sup>†</sup>	34.2% ± 4.7% <sup>†</sup>

\*Disability score range, 13 (normal) to a maximum of 65.  
<sup>†</sup>*P* < .001 vs. baseline; repeated measures analysis of variance.

(1.7 for veterinary scores) versus baseline is noteworthy because the study population of dogs was selected on the basis of having chronic OA conditions that were poorly responsive to conventional therapy. By way of comparison, in the previously reported placebo-controlled study on AD-MSC therapy in dogs with OA of the hip joint,<sup>9</sup> the 90-day effect size versus baseline was approximately 2 in the AD-MSC-treated group compared with 0.4 in the placebo group.<sup>9</sup> Thus, although placebo effects cannot be ruled out, the apparent treatment effects in the present studies are likely largely the result of effects of AD-MSC therapy.

Although the mechanisms responsible for the efficacy of AD-MSC therapy in canine OA are not completely known, many published *in vitro* and *in vivo* studies have explored these mechanisms. Gleaning answers from studies using bone marrow-derived mesenchymal stem cells (BM-MSCs), Ortiz and colleagues<sup>33</sup> reported one particularly intriguing mechanism in that BM-MSCs secrete interleukin-1 receptor antagonist (IL-1ra). The authors determined the IL-1ra to be the specific mecha-

nism that reduced inflammation and fibrosis in a mouse model of lung injury.<sup>33</sup> Recently, Banas and associates reported that human AD-MSCs also secrete IL-1ra, increasing the likelihood that canine AD-MSCs also secrete this cytokine.<sup>34</sup> IL-1 is known to play a significant role in joint disease and is believed to be high in the cytokine cascade in all animal species for which it has been studied.<sup>35,36</sup> Inhibiting IL-1 with IL-1ra has been shown to play a beneficial role in equine OA<sup>37-39</sup> and is one likely mechanism by which AD-MSCs may mediate their effect in canine OA. More studies are needed to support this hypothesis. The well-documented immunomodulatory effects of mesenchymal stem cells represent one therapeutic mechanism in which AD-MSCs may function as well.<sup>8,40-42</sup> AD-MSCs are known to ameliorate severe graft-versus-host disease in people.<sup>42</sup> While AD-MSCs have potential utility solely as a function of their capacity to differentiate, it is being postulated that stem cells also promote tissue recovery through the local delivery and secretion of cytokines and growth factors.<sup>43,44</sup> For example, cell-based tissue regeneration may play a role similar to that seen in the rabbit model of osteochondral defects.<sup>20</sup> One could imagine that the AD-MSCs engraft in synovium and either differentiate or influence their local environment in such a way as to influence differentiation of resident cells.

Blinded, controlled trials will continue to be the gold standard by which to evaluate therapeutic outcomes. It can also be difficult to recruit patients to blinded controlled trials in which there is a chance an owner's animal may not be treated. Because we had already completed a blinded controlled trial, and to give all owners a chance to have their dogs treated, the current study was carried out in a non-blinded, non-controlled fashion. These data are an important addition to the previously reported data that demonstrate that AD-MSC therapy in canine OA is effica-



cious, a clinical outcome that may influence the direction of this therapy in humans.

## CONCLUSION

Overall, dogs with chronic OA of the elbow joint that were treated with intraarticular injection of AD-MSCs demonstrated statistically significant improvement in lameness, range of motion, and pain on manipulation over time compared with baseline values. The veterinary scores were highly correlated with owner scores, indicating that both veterinarians and owners observed similar findings. This multicenter study supports previously published data demonstrating that a single intraarticular administration of AD-MSCs decreases pain and lameness in dogs with OA of the elbow over an extended period after treatment.

## REFERENCES

1. Parker A, Katz A. Adipose-derived stem cells for the regeneration of damaged tissues. *Expert Opin Biol Ther* 2006;6:567-578.
2. Schaffler A, Buchler C. Concise review: adipose tissue-derived stem cells—basic and clinical implications for novel cell-based therapies. *Stem Cells* 2007;25:818-827.
3. Fraser J, Wulur I, Alfonso Z, et al. Fat tissue: an underappreciated source of stem cells for biotechnology. *Trends Biotechnol* 2006;4:150-154.
4. Strem BM, Hicok KC, Zhu M, et al. Multipotential differentiation of adipose tissue-derived stem cells. *Keio J Med* 2005;54(3):132-410.
5. Nakagami H, Morishita R, Maeda K, et al. Adipose tissue-derived stromal cells as a novel option for regenerative cell therapy. *J Atheroscler Thromb* 2006;13(2):77-81.
6. Luyten FP. Mesenchymal stem cells in osteoarthritis. *Curr Opin Rheumatol* 2004;16(5):599-603.
7. Tholpady SS, Llull R, Ogle RC, et al. Adipose tissue: stem cells and beyond. *Clin Plast Surg* 2006;33(1):55-62.
8. Gimble J, Katz A, Bunnell A. Adipose-derived stem cells for regenerative medicine. *Circ Res* 2007;100:1249-1260.
9. Black L, Gaynor J, Gahring D, et al. Effect of adipose-derived stem and regenerative cells in dogs with chronic osteoarthritis of the coxofemoral joints: a randomized, double-blinded multicenter controlled trial. *Vet Ther* 2007;8(4):272-284.
10. Zuk PA, Zhu M, Mizuno H, et al. Multilineage cells from human adipose tissue: implications for cell-based therapies. *Tissue Eng* 2001;7(2):211-228.
11. Varma M, Breuls R, Schouten T, et al. Phenotypical and functional characterization of freshly isolated adipose tissue-derived stem cells. *Stem Cells Dev* 2007;16:91-104.
12. Yoshimura K, Shigeura T, Matsumoto D, et al. Characterization of freshly isolated and cultured cells derived from the fatty and fluid portions of liposuction aspirates. *J Cell Physiol* 2006;208:64-76.
13. Boquest A, Shahdadfar A, Fronsdal K, et al. Isolation and transcription profiling of purified uncultured human stromal stem cells: alteration of gene expression after in vitro cell culture. *Mol Biol Cell* 2005;16:1131-1141.
14. Harman R, Cowles B, Orava C, et al. A retrospective review of 62 cases of suspensory ligament injury in sport horses treated with adipose-derived stem and regenerative cell therapy. *Proc Vet Orthop Soc*, 2006.
15. Vet-Stem, Inc. Data on file, 2005-2008.
16. Dahlgren LA. Use of adipose derived stem cells in tendon and ligament injuries. *Proc Am Coll Vet Surg Symp Equine Small Anim* 2006;150-151.
17. Nixon A, Dahlgren L, Haupt J, et al. Effect of adipose-derived nucleated cell fractions on tendon repair in horses with collagenase-induced tendinitis. *Am J Vet Res* 2008;69(7):928-937.
18. Murphy JM, Fink DJ, Hunziker EB, et al. Stem cell therapy in a caprine model of osteoarthritis. *Arthritis Rheum* 2003;48(12):3464-3474.
19. Guilak F, Awad HA, Fermor B, et al. Adipose-derived adult stem cells for cartilage tissue engineering. *Biotechnology* 2004;41(3-4):389-399.
20. Nathan S, Das De S, Thambyah A, et al. Cell-based therapy in the repair of osteochondral defects: a novel use for adipose tissue. *Tissue Eng* 2003;9(4):733-744.
21. Hedhammar A, Olsson SE, Andersson SA, et al. Canine hip dysplasia: study of heritability in 401 litters of German Shepherd dogs. *JAVMA* 1979;174:1012-1016.
22. Johnson JA, Austin C, Breur GJ. Incidence of canine appendicular musculoskeletal disorders in 16 veterinary teaching hospitals from 1980 to 1989. *Vet Comp Orthop Traumatol* 1994;7:56-69.
23. Moore GE, Burkman KD, Carter MN, et al. Causes of death or reasons for euthanasia in military working dogs: 927 cases (1993-1996). *JAVMA* 2001;219:209-214.
24. Mortellaro CM. Pathophysiology of osteoarthritis. *Vet Res Commun* 2003;27(suppl):75-78.
25. Lascelles BD, Main DC. Surgical trauma and chronically painful conditions—within our comfort level but beyond theirs? *JAVMA* 2002;221:215-222.



26. Budsberg SC, Johnston SA, Schwarz PD, et al. Efficacy of etodolac for treatment of osteoarthritis of the hip joints in dogs. *JAVMA* 1999;214:206-210.
27. Holsinger RH, Parker RB, Beale BS, et al. The therapeutic efficacy of carprofen (Rimadyl-V) in 209 clinical cases of canine degenerative joint disease. *Vet Comp Orthop Traumatol* 1992;5:140-144.
28. Vasseur P, Johnson A, Budsberg S, et al. Randomized, controlled trial of the efficacy of carprofen, a non-steroidal anti-inflammatory drug, in the treatment of osteoarthritis in dogs. *JAVMA* 1995;206(6):807-811.
29. Johnson SA, Budsberg SC. Nonsteroidal anti-inflammatory drugs and corticosteroids for the management of canine osteoarthritis. *Vet Clin North Am Small Anim Pract* 1997;27:841-862.
30. Gingerich D, Strobel J. Use of client-specific outcome measures to assess treatment effects in geriatric, arthritic dogs: controlled clinical evaluation of a nutraceutical. *Vet Ther* 2003;4(1):56-66.
31. Sim J, Wright C. Measures of effect. In: *Research in Health Care*. Cheltenham, UK: Nelson Thornes Ltd.; 2000:288-289.
32. Cohen J. The concepts of power analysis. In: *Statistical Power Analysis for the Behavioral Sciences*. 2nd ed. Hillsdale, NJ: Lawrence Erlbaum Associates; 1988.
33. Ortiz LA, DuTreil M, Fattman C, et al. Interleukin 1 receptor antagonist mediates the anti-inflammatory and antifibrotic effect of mesenchymal stem cells during lung injury. *Proc Natl Acad Sci U S A* 2007;104:11002-11007.
34. Banas A, Teratani T, Yamamoto Y, et al. IFATS series: in vivo therapeutic potential of human adipose tissue mesenchymal stem cells (AT-MSCs) after transplantation into mice with liver injury. *Stem Cells* 2008: Epub ahead of print.
35. Koopman WJ, Moreland LW, eds. *Arthritis and Allied Conditions: A Textbook of Rheumatology*. 15th ed. Philadelphia: Lippincott Williams & Wilkins; 2005:34.
36. Arend W, Malyak M, Guthridge C, et al. Interleukin-1 receptor antagonist: role in biology. *Annu Rev Immunol* 1998;16:27-55.
37. Frisbie DD, Ghivizzani SC, Robbins PD, et al. Treatment of experimental equine osteoarthritis by in vivo delivery of the equine interleukin-1 receptor antagonist gene. *Gene Ther* 2002;9:12-20.
38. Malyak M, Swaney RE, Arend WP. Levels of synovial fluid interleukin-1 receptor antagonist in rheumatoid arthritis and other arthropathies. Potential contribution from synovial fluid neutrophils. *Arthritis Rheum* 1993;36:781-789.
39. Martel Pelletier J, Pelletier JP. Importance of interleukin-1 receptors in osteoarthritis. *Rev Rhum Ed Fr* 1994;61:109S-113S.
40. Nasef A, Mathieu N, Chapel A, et al. Immunosuppressive effects of mesenchymal stem cells: involvement of HLA-G. *Transplantation* 2007;84:231-237.
41. Le Blanc K. Mesenchymal stromal cells: tissue repair and immune modulation. *Cytotherapy* 2006;8:559-561.
42. Fang B, Song Y, Lin Q, et al. Human adipose tissue-derived mesenchymal stromal cells as salvage therapy for treatment of severe refractory acute graft-vs.-host disease in two children. *Pediatr Transplant* 2007;11(7):814-817.
43. Caplan A, Dennis J. Mesenchymal stem cells as trophic mediators. *J Cell Biochemistry* 2006;98:1076-1084.
44. Kilroy G, Foster S, Wu X, et al. Cytokine profile of human adipose-derived stem cells: expression of angiogenic, hematopoietic, and pro-inflammatory factors. *J Cell Physiol* 2007;212:702-709.